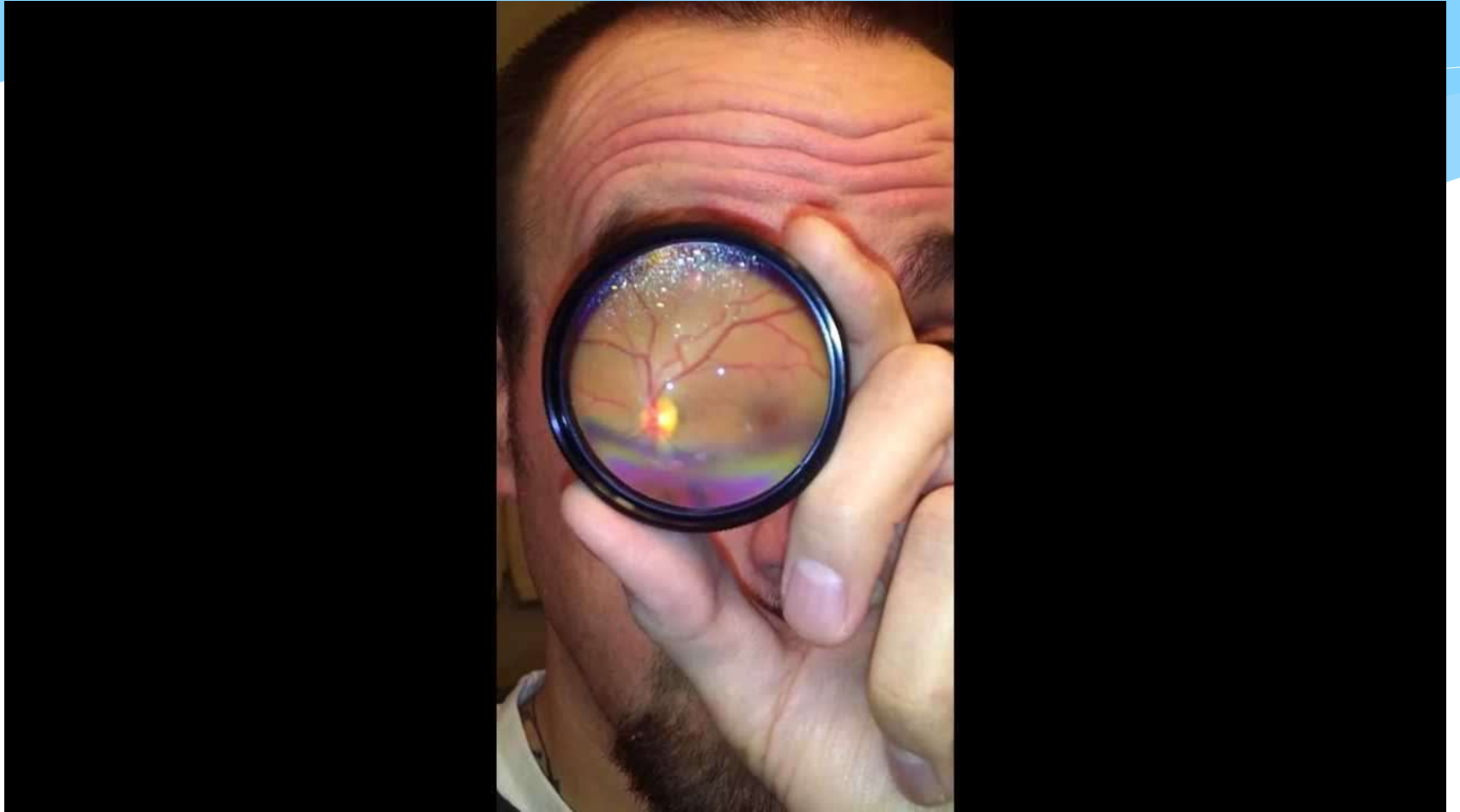

Examination of the eye



By
Dr. Amr Mounir
Lecturer of ophthalmology
Sohag University





Examination

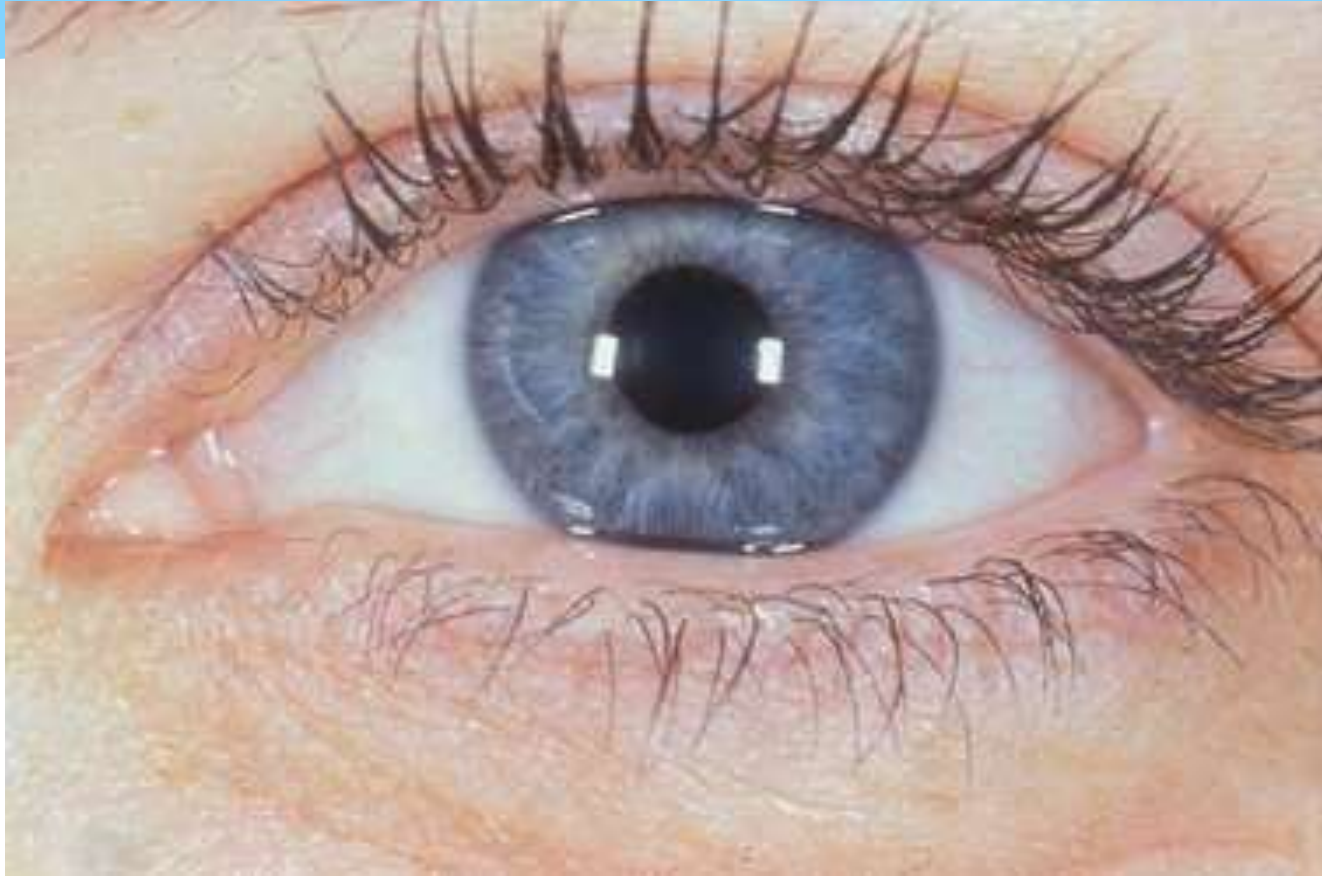
- *1) External Examination**
- *2) Internal Examination
(Fundus)**
- *3) Functional examination**

1) External Examination

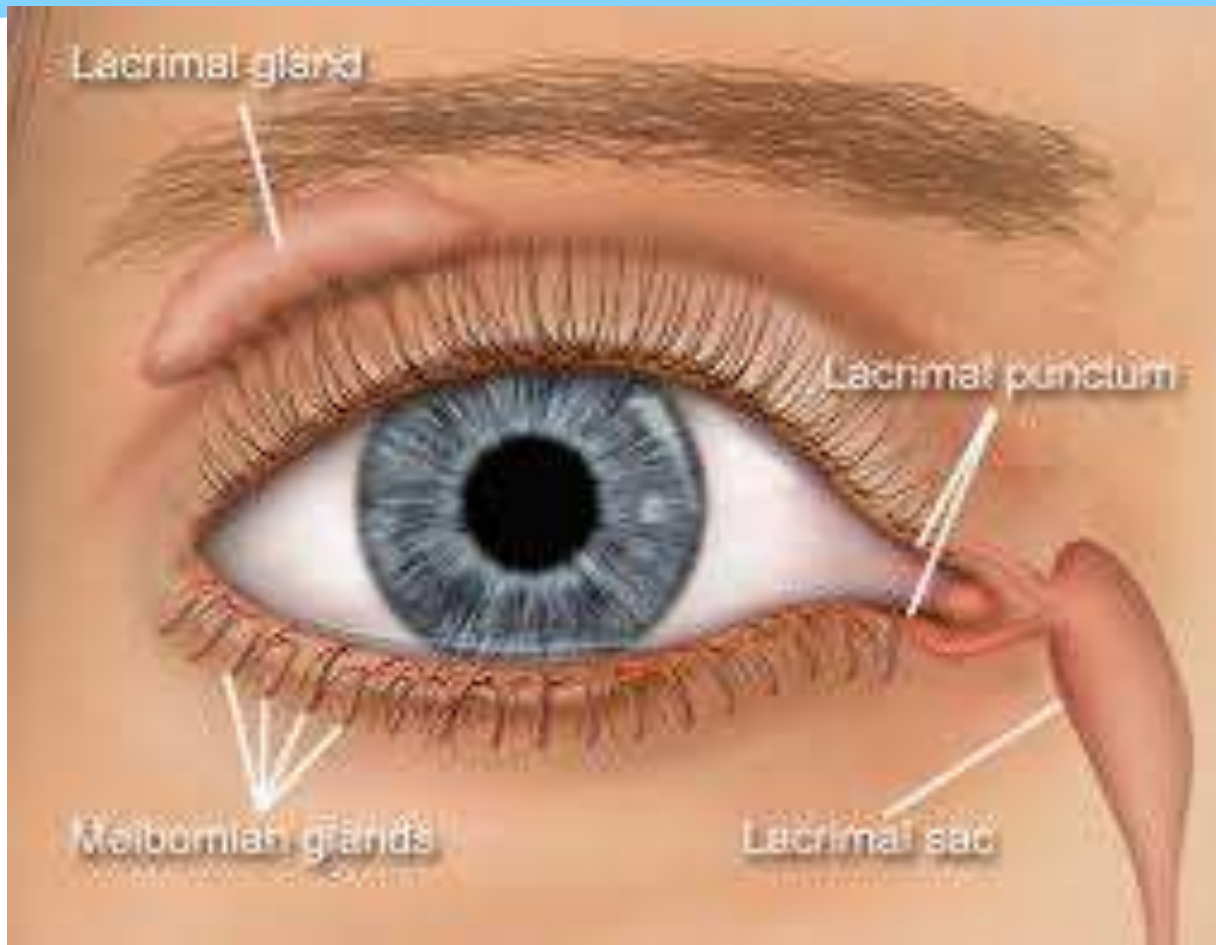
- * **External Appearance**
- * **Lids**
- * **Lacrimal**
- * **Orbit**
- * **Conj**
- * **Cornea**
- * **Sclera**

- * **Anterior chamber**
- * **Iris**
- * **Pupil**
- * **Lens**
- * **IOP**
- * **Extraocular muscles**

Eyelids



Lacrimal System



Orbit

Frontal bone

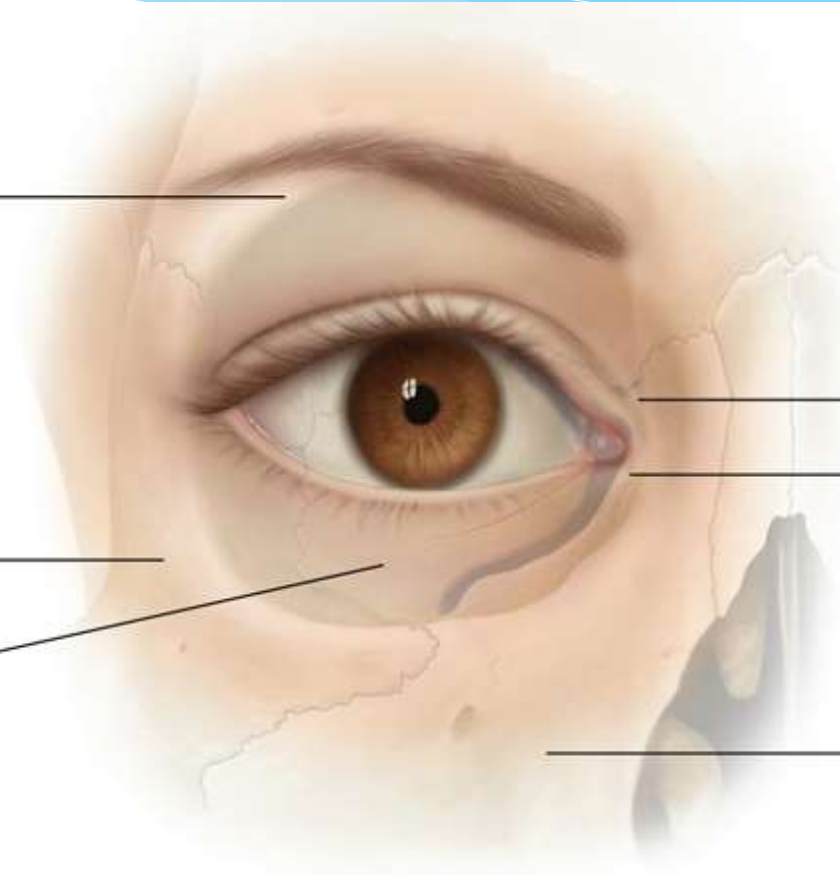
Ethmoid bone

Lacrimal bone

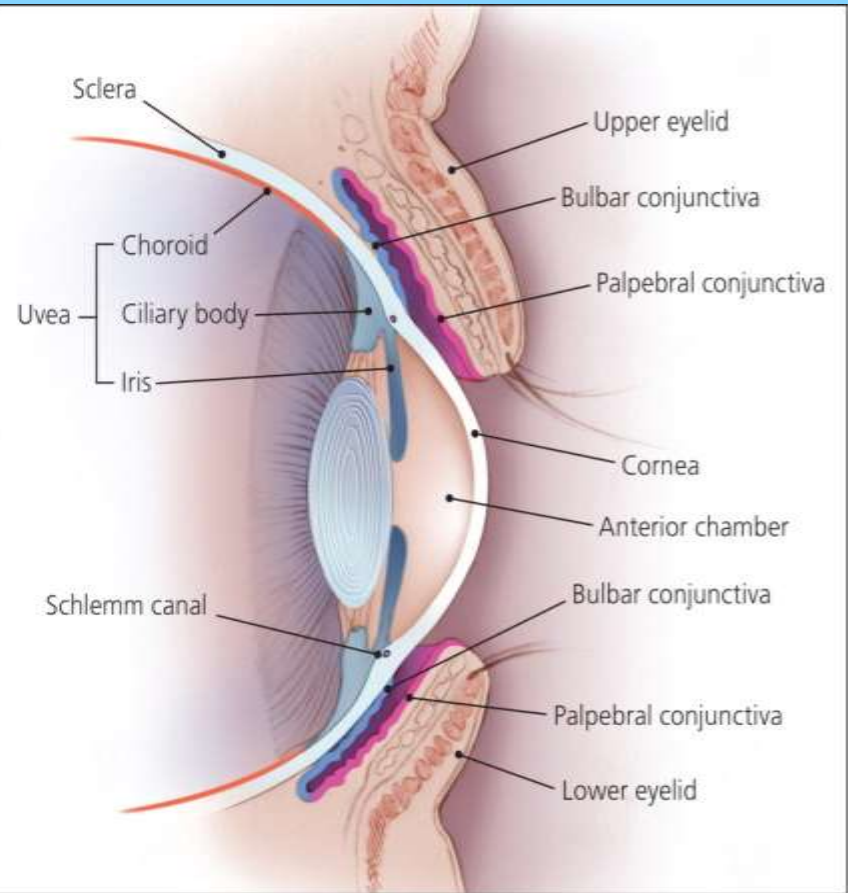
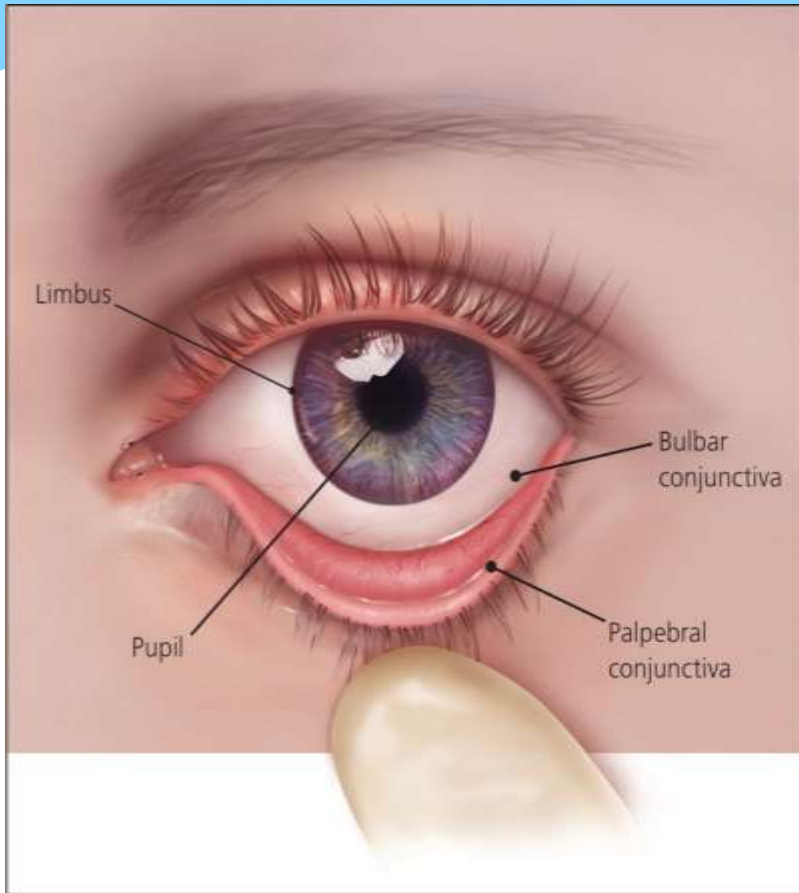
Zygomatic bone

Sphenoid bone

Maxilla

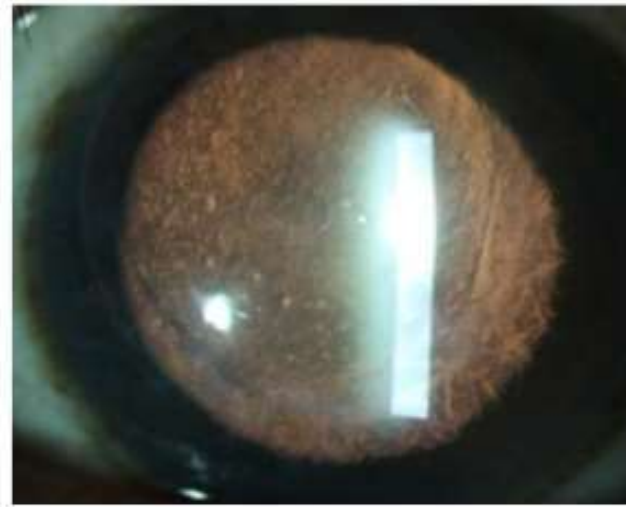
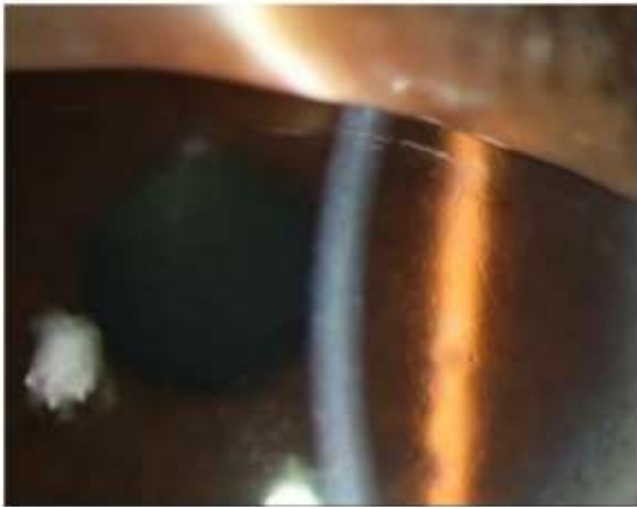

Conjunctiva



Cornea

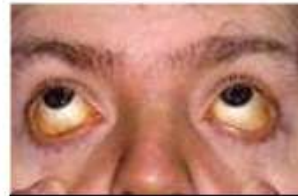Slit Lamp Examination- Retro Illumination



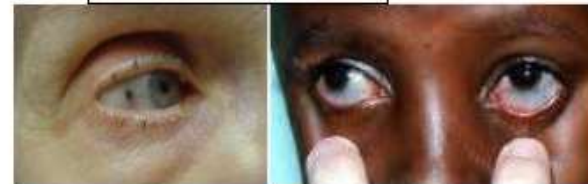Sclera

Examination of sclera

- Color
 - White, yellow, bluish, pigments
- Inflammation, Staphyloma, foreign body entrapped (transparent), perforation



Yellow sclera



Pigments

Blue sclera

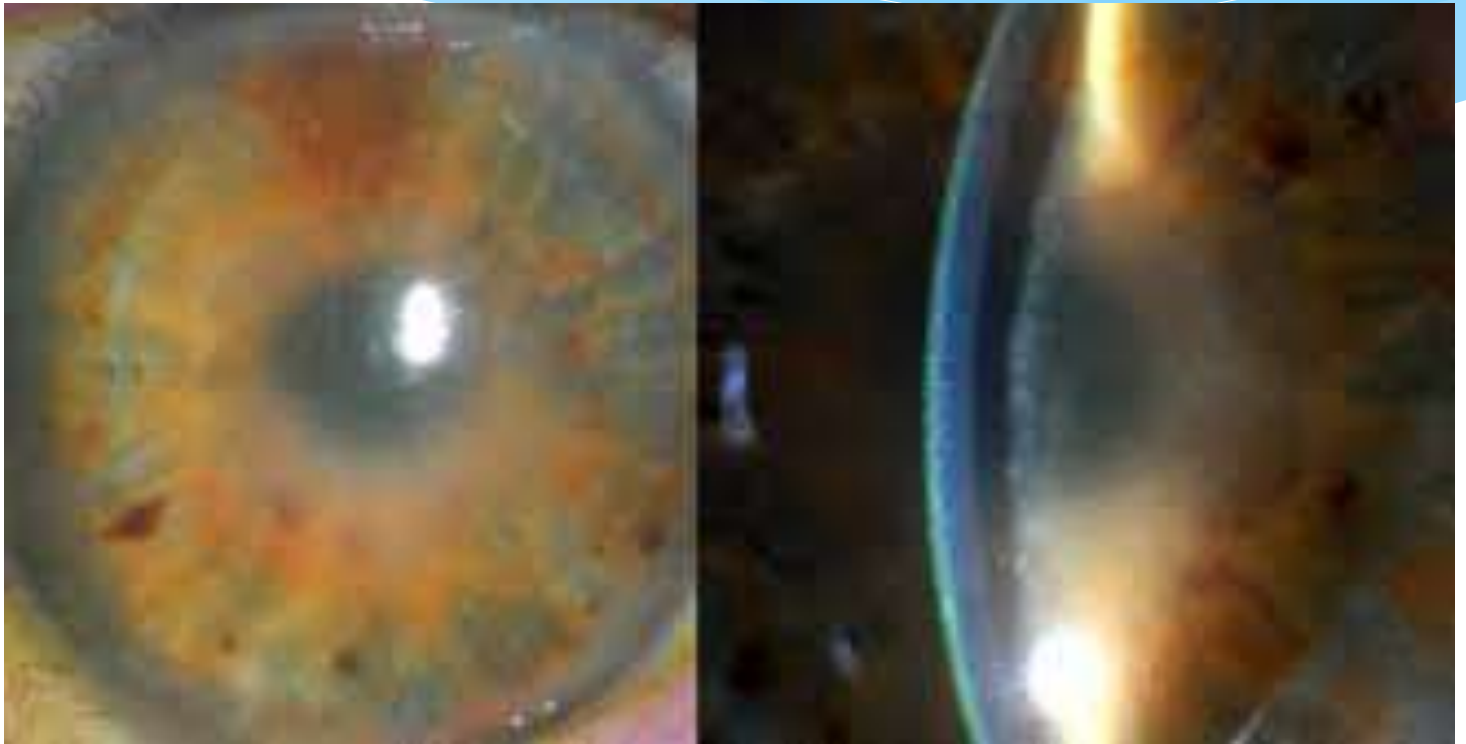


Staphyloma

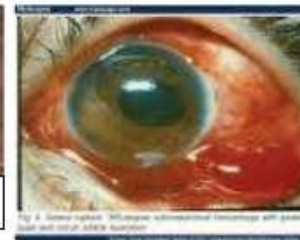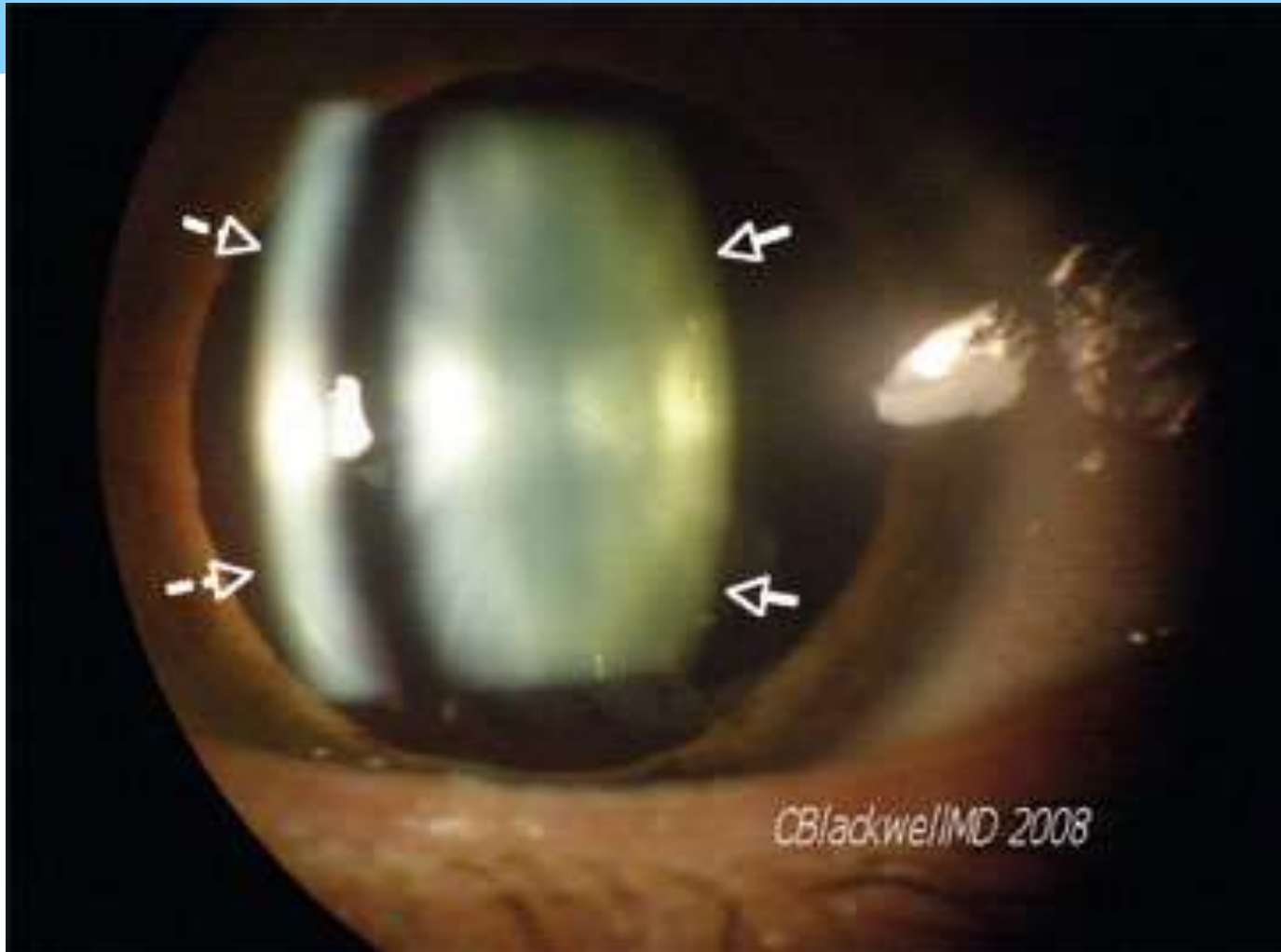


Fig. 4. General system. 2010. http://www.eyewiki.org/wiki/General_system


Anterior Chamber





Lens





Pupil





normal




anisocoria



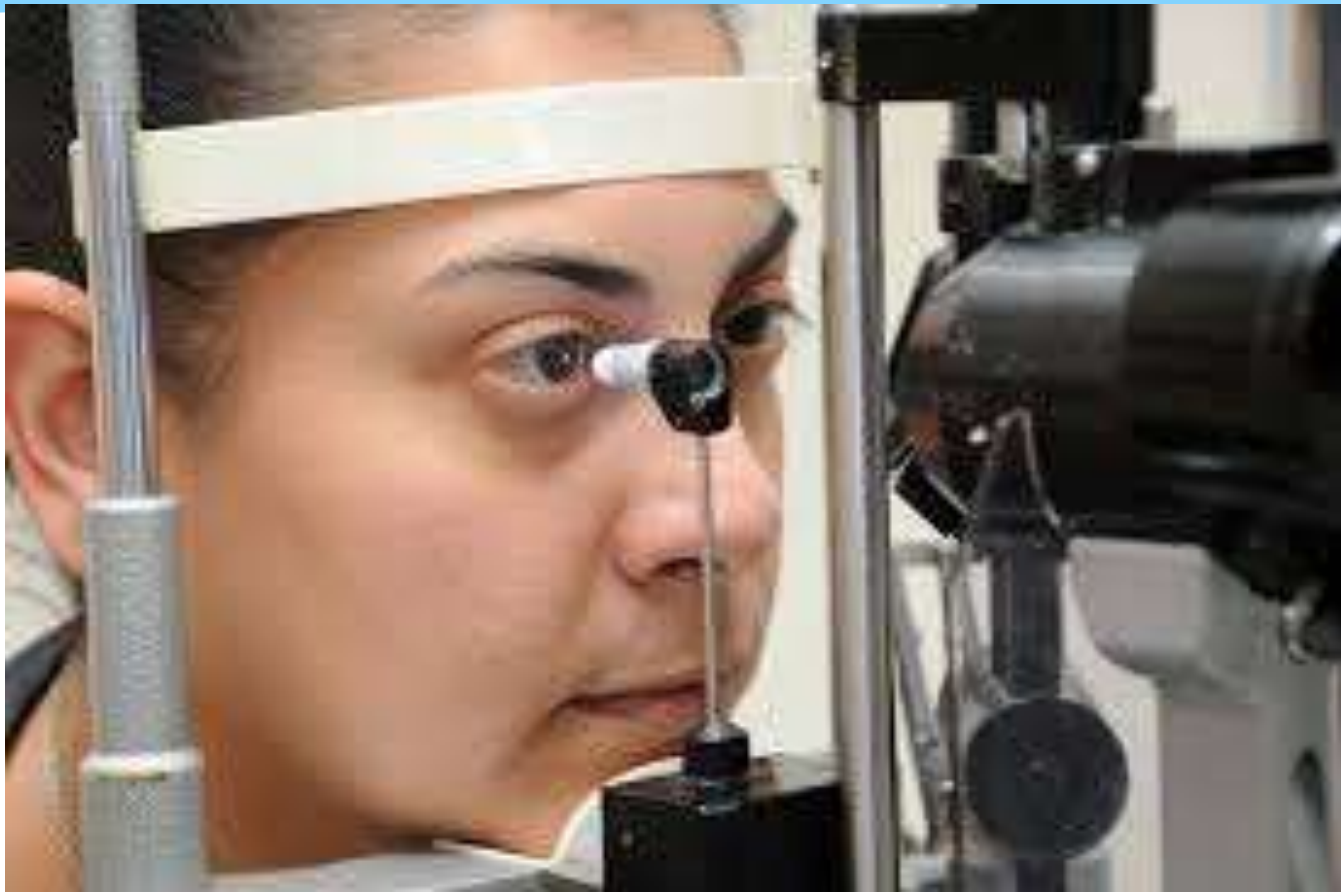miosis



mydriasis



IOP



2) Internal Examination (Fundus)

- * **Retina**
- * **Choroid**
- * **Optic nerve**
- * **Vitreous**

Extra-ocular muscles